

pISSN 1978-2071
 eISSN 2580-5967
 Jurnal Ilmiah Kedokteran
 Wijaya Kusuma (JIKW)
 Volume 11, No. 1 Maret 2022

AUTHORS' AFFILIATIONS

Departemen Bedah Orthopaedi,
 Fakultas Kedokteran UPN Veteran
 Jakarta^{1,2}
 Departemen Bedah Orthopaedi,
 Rumah Sakit Al Fauzan Jakarta³

CORRESPONDING AUTHOR

Basuki Supartono
 Departemen Bedah Orthopaedi
 Fakultas Kedokteran UPN
 Veteran Jakarta
 Jl. RS Fatmawati, Pondok Labu,
 Jakarta Selatan 12450
E-mail:
 basuki@upnvj.ac.id

Hormone Therapy as A New Hope for Achondroplasia Patients

Basuki Supartono^{1*}, Ayola Dewi Utami², Abyanka Rayhan Fuadi³, Bintang Bayu Aryandi¹

Abstract

Achondroplasia is a disorder of child bone growth due to gene mutation of growth factor receptor. Short stature is a major problem. Efforts to increase height are still a challenge. The method performed so far is the lengthening of the limbs with various complications and risks of re-surgery. A promising new alternative without surgery is the administration of growth hormone therapy. This review aims to find out the safety and effectiveness of hormone therapy. The review method used is a narrative review. The review results showed that growth hormone therapy is safe and effective. The review concludes that growth hormone therapy has been proven to be safe and effective in increasing the height of achondroplasia patients.

Keywords: Achondroplasia, Short Stature, Growth Hormone Therapy, Limb Lengthening.

Review Article

Terapi Hormon Pertumbuhan Harapan Baru bagi Penderita Akondroplasia

Abstrak

Akondroplasia adalah gangguan pertumbuhan tulang anak akibat mutasi gen reseptor faktor pertumbuhan. Masalah utama yang sering dikeluhkan adalah tinggi badan yang pendek. Namun upaya meningkatkan tinggi badan masih menjadi tantangan. Metode yang dilakukan selama ini adalah operasi. Operasi pada pasien akondroplasia menimbulkan banyak komplikasi

dan risiko operasi ulang. Alternatifnya adalah pemberian terapi hormon pertumbuhan. *Review* ini bertujuan untuk mengetahui keamanan dan efektifitas terapi hormon. Metode yang digunakan adalah *review* naratif. Hasil *review* memperlihatkan bahwa terapi hormon pertumbuhan aman dan efektif meningkatkan tinggi badan pasien akondroplasia. Kesimpulan *review* adalah terapi hormon pertumbuhan aman dan efektif untuk meningkatkan tinggi badan penderita akondroplasia.

Kata Kunci: Akondroplasia, Pendek, Terapi Hormon Pertumbuhan, Pemanjangan Tungkai.

INTRODUCTION

Achondroplasia is a dysplasia disease in children (Coi *et al*, 2019) and one of the skeletal growth disorders that are frequently found (Pauli, 2019). The patient has a specific posture and short stature. Besides bone growth disorder, achondroplasia can also cause musculoskeletal disorders (Foreman *et al*, 2020).

According to the artifact found around the world, this disease has been known since thousands of years ago. Achondroplasia has been studied scientifically for fifty years. However, the study continues, especially for the management of this disease. There is a lot of guidance about the therapy, such as from the American Academy of Pediatrics. Nevertheless, there is no standard guideline on solving patient height (Pauli, 2019).

There have been studies about surgery therapy, but there is none from growth hormone. So, this literature review study will discuss the growth hormone therapy in achondroplasia patients as an alternative to surgery.

Epidemiology

The prevalence rate of achondroplasia varies around the world, about 2.5 – 10 per 100.000 birth (Foreman *et al*, 2020). In Europe, about 3.72 per 100.000 births, although the data is still not available in Indonesia. The rate is possibly not accurate because there are a lot of terminated pregnancies because the fetus has been diagnosed with achondroplasia. The rate of terminated pregnancy caused by achondroplasia increases due to increasing the prenatal diagnostic method (Coi *et al*, 2019). The newest prevalence rate data is 4.6 per 100.000 birth (Wrobel *et al*, 2021).

Etiology

Achondroplasia is caused by the mutation of the 3rd gene receptor of the Fibroblast Growth Factor (FGFR3) (Ornitz and Legeai-mallet, 2018). FGFR3 is a gene that makes a specific protein to change the cartilage to become bones (Daugherty, 2017). The mutation happened in the 4th chromosome that can be seen by substituting arginine with glycine (p.Gly308Arg). Fibroblast Growth Factor (FGF) is one of the sign molecules important in body regeneration. FGF is found in the chondrocyte and bone cells to regulate bone growth. The mutation caused the sign through several mechanism combinations such as stabilizing the receptor, increased dimerization, and increased tyrosine kinase activity. The sign increase would depress the proliferation process and the maturation of the growth plate of the chondrocyte. As a result of the growth plate volume, bone trabecular tissue volume and bone elongation process will decrease.

This increased signal suppresses the proliferation and maturation of growth plate chondrocytes. As a result, there is a decrease in the volume of the growth plate, the volume of bone trabecular tissue, and the process of bone elongation (Ornitz and Legeai-mallet, 2018).

Achondroplasia is the dominant autosomal inherited; that is why children with an achondroplasia father and a normal mother will have a 50% risk. However, achondroplasia

mutation can happen spontaneously (Pauli, 2019). It explains why achondroplasia babies could be born from normal, healthy parents (Unger *et al*, 2017).

Naturally, bone growth starts in babies, children and increases actively in puberty and will decrease at the age of 15 and stop at the age of 18. Bones elongation results from the growth plate activity and the bone ossification center. These structures will be disturbed when FGFR3 mutates (Legeai-Mallet and Savarirayan, 2020).

Chondrocyte proliferation and differentiation on the growth plate were controlled by mechanical factors such as gravity, muscle contraction, hydrostatic pressure, and growth factor (Ornitz and Legeai-mallet, 2018). Growth factor receptor mutation (FGFR3) will push the chondrocyte differentiation and proliferation of the cartilage matrix. This process will disturb the endochondral ossification process that causes the patients to become short, which is called dwarfism (Kubota *et al*, 2020). Almost all the symptoms and medical problems of achondroplasia patients arise from these (Pauli, 2019).

Clinical Feature

Nowadays, prenatal diagnosis results are more accurate; ultrasonography will ensure achondroplasia is suspect since gestational. These diagnoses can be known from 20 weeks of pregnancy (Savarirayan *et al*, 2018). Early diagnosis is important for the management of achondroplasia, especially for prevention.

The diagnostic criteria have no agreement, but achondroplasia has the general characteristic (Pauli, 2019). The general characteristics are short-statured (Ceroni *et al*, 2018). The patient height is about 124 cm in women and 130 cm in men (Kubota *et al*, 2020).

Besides being short-statured, the other profiles are big-sized heads, vertebrae deformity, and fingers form (trident). (Picture 2) (Ceroni *et al*, 2018). Beside the proximal part of the upper arm and leg shorter than distal part, protruding forehead, sunken nose bridge, skull base shorter and narrowed chest (Picture 1).

The other characteristics are foramen magnum stenosis, ventricle enlargement, hydrocephalus, and canal spinal stenosis. It is caused by endochondral ossification disorder, which often happens in the vertebrae and the skull

base region (Bhusal *et al*, 2020). The other profiles are unproportional limb length, midfacial retrusion, small chest cavity, stiff elbow joint, hypermobility knee joint and hip joint, deformity

knee joint (genu varum), and decreased muscle tone. Not all the symptoms can be seen in babies or children with achondroplasia (Pauli, 2019).

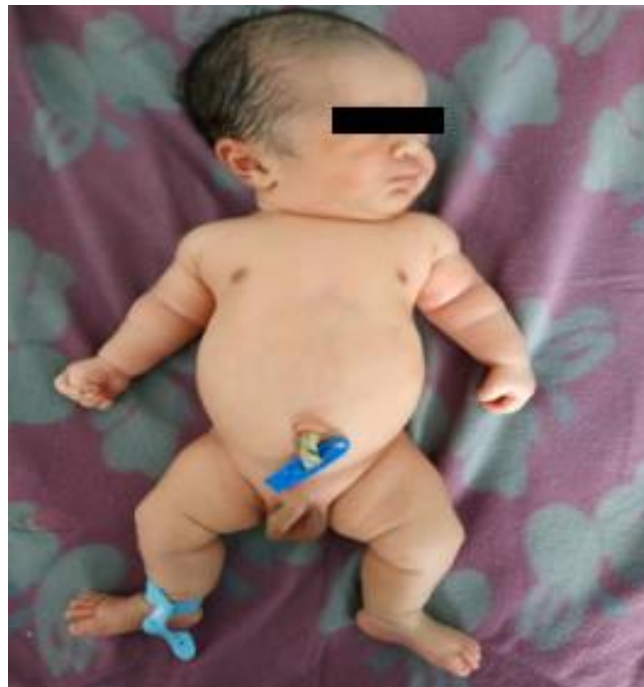

Figure 1. Clinical feature of achondroplasia in the newborn (Bhusal *et al*, 2020).

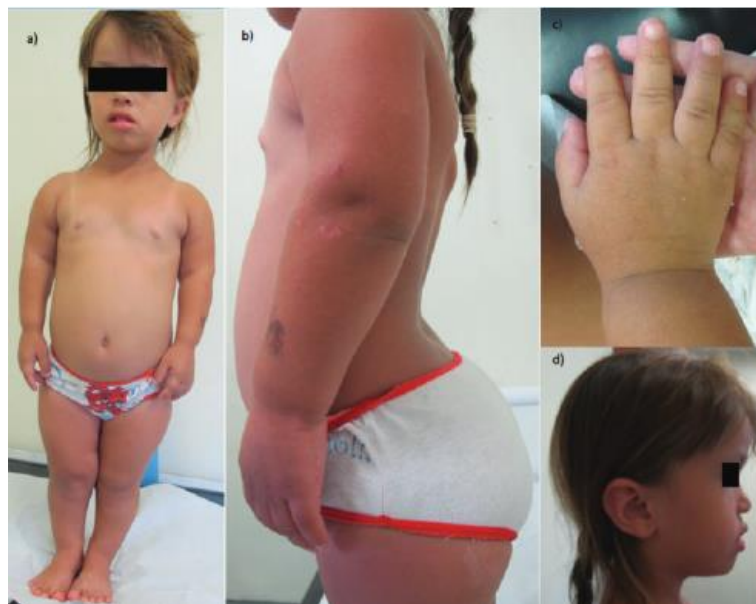

Figure 2. Achondroplasia patient profile : (a) short limb, big sized head (b), kyphosis and lordosis (c), trident hand, short fingers (d), protruding forehead (Ceroni *et al*, 2018).

Radiological examination is important for diagnostic confirmation, such as infantogram in infants that is seen in picture 3 (Bhusal *et al*, 2020). Hip joint and femur radiological image look typical: horizontal acetabulum, narrow sacral bone notch, the proximal part of the femur looks darker, short,

and sturdy (Pauli, 2019). The other radiological images are femur neck shorter and tubular thickening. Long bone metaphysis widens and has an irregular shape, known as cupping. And also, there is femur neck shorten (Kubota *et al*, 2020).

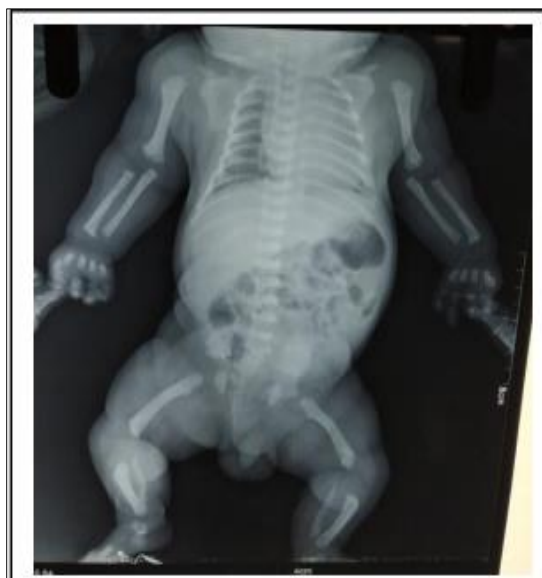


Figure 3. Infatogram : humerus and femur shorten (Bhusal *et al*, 2020).

Besides achondroplasia, short stature profiles can also be found in rickets (Supartono *et al*, 2021). To make the diagnosis, it needs analysis of DNA examination because the clinical feature and radiological image may have some uncertainty. Almost all achondroplasia has FGFR3 gene mutation, 98% changed in c.1138G>A, and the rest has c.1138G>C gene mutation. The important differential diagnoses are hypochondroplasia, pseudoachondroplasia, thanatophoric dysplasia, Sattan Syndrome, Crouzon Syndrome, and Muenke Syndrome (Pauli, 2019).

Natural History of Achondroplasia Patient

Achondroplasia patients may be born with normal body lengths but shorter stature than normal children. At three months, there is potential damage to the medulla spinalis layer and vertebrae- skull joint (craniocervical junction). This can cause sudden death, which often happens to 3-11 months old babies.

Other comorbidities were lung restrictions and neurologic disorders such as hydrocephalus, brain hematoma and seizure even apnea. In the next age, it could be orthopedic disorders such as deformity of the vertebrae like kyphosis, lordosis, and vertebrae stenosis. Achondroplasia patients have hard experiences extending their elbow joint. The other deformities were body joint hypermobility and an O-shaped knee (bowleg).

There is no intellectuality problem in patient achondroplasia; they can go to school as usual (Pauli, 2019). However, they experienced a

decreased quality of life than normal children of the same age (Backeljauw *et al*, 2021; Pauli, 2019).

Achondroplasia has more impact on teenagers. Achondroplasia teen patients have often experienced physical complaints, limited daily activity, and psychosocial problems. They often complain that they get tired very easily (Pfeiffer *et al*, 2022).

In children, the complaints of pain are felt mainly on the knee joint, and in adults, the pain is more often in the vertebrae. This condition makes the patients can't do their work maximally and will impact their economic status (Wrobel *et al*, 2021). They feel different from their friends, frightened and unconfident. They experience stigmatism and bullying frequently (Pfeiffer *et al*, 2022).

Adults with achondroplasia patients can live a normal family, have a pregnancy, and give birth. However, the delivery process should be done by section caesar. They could live to old age, but their life expectancy are lower than normal people (Pauli, 2019).

The main problem that they complained about is height. This short stature caused problems and affected daily activity. Achondroplasia children feel different; they are different from their friends. This situation makes them feel isolated from their friends and makes them have difficulty communicating and social life. The achondroplasia children also experienced disruption in physical activity participation and play. It can be seen in their emotion that they are easily offended, angry and even feeling lonely (Wrobel *et al*, 2021).

Achondroplasia patients have difficulty reaching higher stuff; they need someone or special tools such as step tools. This condition impacts their learning activity in school, requiring more time to adapt to the environment and learning activity in school (Pfeiffer *et al*, 2022).

There is no definitive therapy for the negative effect of gene mutation on bone growth (Pauli, 2019). The effort to increase the height of the achondroplasia patient is still challenged. The method used now is surgery, but this procedure has a lot of complications (Hosny, 2020). There is much literature about limb lengthening by surgery; however, there is barely any literature that reviews hormonal therapy as an alternative therapy, especially the effectiveness and safety. Because this is important for the achondroplasia patient, we try to review the literature on the effectiveness and safety of hormonal therapy for achondroplasia patient growth.

METHODS

The literature review study used a narrative review method. To answer the goals, the writer has been compiled empirical evidence. The search was done using google scholar and PubMed. The used keywords were achondroplasia, short stature, growth hormone therapy, limbs elongation. The inclusion criteria were national and international journal articles from the research results and case report. Searching was done using the English language.

RESULT

Thirteen literature was found, five literature about surgery therapy, five about hormonal therapy, and three about the malignancy risk of hormonal therapy. Surgery literature was from Korea (Park *et al*, 2015), Spain (Ginebreda *et al*, 2019), the United States (Paley, 2021; Shabtai *et al*, 2021), and Kazakhstan (Dossanov *et al*, 2021). All the literature used patients' medical records. The hormonal therapy literature was from Japan, Europe (Hertel *et al*, 2005) Italy (Miccoli *et al*, 2016), Macedonia (Krstevska-Konstantinova *et al*, 2016).

The research design for the hormonal therapy literature was a clinical study (Tanaka *et al*, 1998), random therapy dose (Hertel *et al*, 2005), cohort study (Harada *et al*, 2017), case reports (Krstevska-Konstantinova *et al*, 2016) and

meta-analysis (Miccoli *et al*, 2016). Hormonal therapy malignancy literature was designed as a cohort study (Swerdlow *et al*, 2015, 2018) and literature reviews (Cianfarani, 2019)

DISCUSSION

Almost all the literature discussed the benefit and risk of increasing height therapy in achondroplasia patients. The mechanism of achondroplasia was discussed from a basic science perspective. The definition, etiology, screening, diagnosis, and management of the disease were discussed clinically. The literature shows the scientific evidence of achondroplasia patient therapy. The review results show that patient height can be increased. Non-surgery therapy such as growth hormone administration was effective and safe to increase the height. A detailed explanation can be seen below:

Can achondroplasia patients' height be increased?

The height of achondroplasia patients can be increased, but there is no consensus until now. A lot of research has been done on several methods. The choices are bone lengthening, hormonal therapy, or both combinations.

The bone lengthening was done through lengthening the lower limbs surgery like the femur bone tibia (Ko *et al*, 2019). The lengthening of upper limbs, such as the humerus, can't increase the height but only to reduce the pain and for cosmetic purposes only (Ginebreda *et al*, 2019).

The lower limb lengthening surgery is commonly done in two stages with one or three years intervals. The surgery can be done in two stages. Park from Korea did this first surgery by lengthening the tibia bone first and then lengthening the femur (Park *et al*, 2015). Shabtai from the US did this surgery by lengthening the tibia and femur together simultaneously, and for the subsequent surgery done the same step. This method aims to reduce complications and achieve the length needed (Shabtai *et al*, 2021).

Paley has done this surgery with one step only, lengthening the femur and tibia at the same time. Achieving normal height requires lengthening the bone about 30 cm (in women) and 40 cm (in men). The maximum of bone lengthening must be according to the bone segment of each surgery, about 15 cm for the tibia and 10 cm for the femur, or a total sum of 25 cm (Paley, 2021).

Osteotomy and distraction are the principles of bone lengthening. Bone lengthening was done gradually (gradual distraction) using an external fixator. However, now, it can be done using an internal fixation (Paley, 2021).

Paley succeeds in increasing the patient height around 12-40 cm with the median of 27 cm, so it is in the normal height range. Nevertheless, this surgery causes weakness (paraparesis) in one of the patients (Paley, 2021).

Surgery on achondroplasia children was done in some countries such as Korea (Park *et al*, 2015), India, Great Britain, Japan, Italy, Kazakhstan, Hongkong, Spain, and the US (Dossanov *et al*, 2021; Paley, 2021). The age of the children that have surgery varies from 7 – 27 years old (Paley, 2021). The surgery under the age of 7 years old (girl) and an eight-year-old (boy) can delay bone growth. Moreover, the parents have objected that the genu varum was corrected at this age (Paley, 2021).

The ethics expert and health care provider in the US criticized the age of the surgery, which is too young, and they suggest that the surgery is at the older age when they can make the decision. When the children can understand the surgery procedure and give their approval. Because the surgeries are complex and have high complications, it is wise to take place at the main referral hospital. The hospital has good facilities and comprehensive care (Pauli, 2019).

Park has reported a retrospective study about the surgery result of an achondroplasia patient in Korea. The research involved 28 men and women aged 5 to 21 years old. Surgery procedures were conducted in two stages. First, lengthening the tibia using an Ilizarov ring fixator, and the second is lengthening the femur using a monolateral external fixator tool. With the interval between the second surgery about 9 to 48 months. Bone lengthening will be done seven days after surgery with 1 mm/per day (Park *et al*, 2015).

According to Park, the surgery caused many problems, obstacles, and complications. The problem mostly appears as a pinhole infection in the tibia or femur. This can be overcome with antibiotic administration. Another surgery obstacle is the appearance of a deformity like equinus varus, genu valgum, imperfect bone consolidation, hip joint contracture, knee joint contracture, and systemic infection. Another surgery complication is a bone fracture in the

osteotomy region and varus deformity of the femur. The obstacles and complications can be fixed by re-surgery like debridement, deformity correction, muscle resection, osteotomy, and orthopedic implant installation (Park *et al*, 2015).

Bone lengthening surgery complications were influenced by the kind of bone, length of bone, lengthening distances, and surgery method. The complications increase on the femur, and when the lengthening of the bone more than 20% of the original bone length. If the bone lengthening is about 5 to 8 cm, then the complication risk is moderate; the risk becomes higher if the lengthening is more than 8 cm. How long the bone can be lengthened depends on the bone and soft tissue condition and the range of motion (Shabtai *et al*, 2021).

Park can lengthen the bone until 182 mm, about 98 mm (55%) from the tibia and 84 mm (37%) from the femur; this can be because the patient's healing ability is good soft tissues are elastic, and the muscle length long enough. The tibia's complication rate is lower than the femur because the tibia regeneration capability is good. The femur regeneration in achondroplasia patients is atrocious and often makes femur complications post-surgery fractured and arched (angulation) (Park *et al*, 2015).

The other complication is ankle muscle contracture, so the joint is abnormal (equinus deformity). Contracture can be turned out in the hip joint and knee joint muscles (Pauli, 2019). The unstable knee joint will lead to a degenerative joint disease (Supartono, 2018).

The time needed for the recovery of bone after surgery is six months, and the bone strength will be normal in 2 years. After the bone lengthening surgery, patients should walk using a cane to avoid complications such as fractures, poor callus formation and angulation deformity. So, patients should walk with a cane and can walk without it when an external fixator has been removed. Another complication is poor bone regeneration. If this turns out, bone distraction should be temporarily suspended. Bone distraction should be done step by step (Park *et al*, 2015).

Park reported that the surgery method in Korea was bilateral sequential femoral and tibia lengthening. The rate of complication for the tibia was 46% and for the femur until 72%. The rate of re-surgery for the tibia was 27% and femur was

66%. Nevertheless, Park believes surgery is still the right choice to improve patients' quality of life. With one condition, the surgeon should closely monitor and can overcome the complication (Park *et al*, 2015). That is why the surgery must be well done to avoid complications (Pauli, 2019).

Shabtai has been doing simultan surgery for both the tibia and femur left and right (*bilateral sequential femoral and tibial lengthening*) but in two steps. The goal is to reduce complications. The first step is lengthening the tibia and femur about 4 cm and 6 cm. After three years, the patients have to undergo subsequent surgery and lengthen the tibia about 5-7 cm and the femur about 6-8 cm. The lengthening achieves 20-25 cm in total with the complication rate of the surgery was 39% and the rate of the re-operation was 16%.

Shabtai described that surgery gives stress to patients and their bodies. It can caused side effects such as skin contracture, tissue damage, growth plate disorder, peroneal nerve lesion, compartment syndrome, bone recovery disorders like malunion and non-union (Shabtai *et al*, 2021).

To reduce complications, Bossanova from Kazakhstan developed a bone fixator with a rod

monolateral fixator. This tool has many benefits: good performance, lightweight, strong, stable, safe, comfortable, cheap, and easy maintenance. Other benefits are the minimal tissue damage and the time of fixation is shorter. This kind of external fixator was removed after three months, one-third of the time usually used. The healing of the bone was faster, with minimal pain and deformity. However, the complications are still there, such as Achilles tendon shortening inflammation, tissues infection, ankle contracture, and other joints (Dossanov *et al*, 2021).

Paley is a bone lengthening expert from the US that most experienced and said that achondroplasia surgery is still controversial. The long-term effect is still unknown. Maybe patients became tall but still cannot get rid of the chance of joint degeneration and other complications in the future. With non-surgery therapy, perhaps the surgical therapy will be abandoned. Surgery will be done only for adults that need bone lengthening (Paley, 2021). The results of the achondroplasia surgery can be seen in Table 1 below.

Table 1. The Results of Achondroplasia Patient Surgery from Studies in Asia, US, and Europe

Researcher	Park	Ginebreda	Shabtai	Bossanova	Paley
Year	2015	2019	2021	2021	2022
Country	Korea	Spanyol	Amerika	Kazakhstan	US
Study Design	MR	MR	MR	<i>Clin. study.</i>	MR
Surgery Method	<i>SeBL</i>	<i>BILL</i>	<i>SiBL</i>	<i>SiBL + BILL</i>	<i>SeBL + SiBL+ BILL</i>
Osteotomy	TT/FF	HH	TFTF/TFTF	TTFHH	TTFHH
Implant	<i>REF</i>	<i>MEF</i>	<i>REF</i>	<i>MEF</i>	<i>Hybrid</i>
Fixation Length	360 days	220 days	360 days	88 days	360 days
Total Patients	28 children	55 children	50 children	14 children	75 children
Patients Age	9 - 20 yrs	12 – 25 yrs	12 – 14 yrs	5 – 15 yrs	7 - 16 yrs
Step	Two steps	1 step	Two steps	1 step	1 step
Surgery Gap	9 – 48 months	-	42 months	-	12 months
Bone Lengthening	+ 182 mm	56 mm	+ 124 mm	+ 164 mm	+ 270 mm
Complication	T:41%,F:68 %	22 %	39 %	100 %	Lumpur
Re-surgery	66 %	-	45 %	100 %	-

Description:

MR: Medical Record, Clin. study: Clinical Study, SeBL: Sequential bilateral limb lengthening, BHL: bilateral humeral lengthening, SiBL: Simultaneous bilateral limb lengthening, T: Tibia, F: Femur, H: humerus, REF: Ring external fixator, MEF: monolateral external fixator, Hibrid: REF, MEF, Internal Fixator,

According to Miccoli, growth hormone therapy has benefits for achondroplasia patients (Miccoli *et al*, 2016). The hormone that is used is synthetic growth hormone (r-hGH). This preparation triggered the bone growth by the insulin growth factor (Cianfarani, 2019) that is

stimulated IGF-1 in the chondrocyte nucleus (Wrobel *et al*, 2021).

Growth hormone therapy for achondroplasia patients has been studied with various doses and various research periods, given by sub cutan injection daily or weekly. The daily

dosage is 0.1 IU (0.033 mg)/kg or 0.2 IU (0.066 mg/kg (Hertel *et al*, 2005). Moreover, the weekly dosage is 0.16 – 0.42 mg/kg (Miccoli *et al*, 2016). The length of therapy varies from 2 years (Tanaka *et al*, 1998) until ten years (Harada *et al*, 2017). The r-HGH therapy has been used since 1985 for growth hormone deficiency, but right now, it is used for achondroplasia patients. Since 1997 Japan has officially used r-hGH for achondroplasia patients (Cianfarani, 2019).

Tanaka reported r-HGH administration weekly for 42 achondroplasia children aged 3- 14 years old in 1 – 3 years. There are two dosages of administration which are 0.5 IU/kg and 1.0 IU. This therapy proved it could accelerate bone growth speed from 3.9 cm/years to 6.5 cm/years in the first year and become 5.3 cm/ years in the third year. This therapy was effective and safe to increase body height of the achondroplasia patient (Tanaka *et al*, 1998).

Hertel reported that this therapy was safe without side effects. Hertel has done a randomized clinical study for four years on 35 achondroplasia patients from Europe. Twenty children were girls aged between 4 – 10 years old and 15 boys aged 4 – 12 years old. The inclusion criteria were clinical diagnosis, radiologic diagnosis, and age. Exclusion criteria were endocrine disease, the growth hormone therapy before puberty, and the height addition last year more than 2.5 cm/year. Patients are randomly divided into 2 dose groups that are 0.1 IU (0.033mg)/kg/day and 0.2 IU (0.066mg)/kg/day. Patients get therapy for two years, one year of cessation, and back to therapy again for another two years. The results showed that the growth speed accelerated about 1.9 cm/year (low dose) and 3.6 cm/year (high dose) (Hertel *et al*, 2005).

Krstevska-Konstantinova reported a boy, ten years old from the normal parent diagnosed achondroplasia during mother pregnancy. Clinically psychomotor development was normal, but they had speech disorder and genu varum. According to genetic examination results, there were a heterozygote mutation c1138 in gene FGFR3. At the age of 3 years and 4 months old, the patient has a height of 82,3 cm and a weight of 14 kg, has started growth hormone therapy with dose administration of 0.06mg/kg. The growth satisfied and the height addition each year is achieved by the third percentile of the growth curve for 10 years old normal children. The therapy result was safe and effective for increasing the children's height (Krstevska-Konstantinova *et al*, 2016).

Miccol *et al* reported meta-analysis results from 12 reports with 555 teen achondroplasia patients given rhGH with doses of 0.21mg/kg/weekly. The results proved that hormone administration for 5 years was safe and effective in increasing the height of the patients. This therapy had no proven side effects such as acromegaly and neurologic disorders (Miccoli *et al*, 2016).

Harada *et al* reported a retrospective cohort study on 22 achondroplasia patents. The therapy started from the age of 3 years old for 10 years. The height addition achieves 3 cm, 10 cm, and 17 cm for the hormonal group, hormonal with tibia surgery group, and hormonal with tibia and femur surgery group, respectively (Harada *et al*, 2017).

The surgery was effective in increasing the height but caused so many complications. Growth hormone therapy was suitable for achondroplasia patients because it was safe and effective (Harada *et al*, 2017). A comparison of the hormonal therapy result from many studies can be seen in Table 2 below.

Table 2. Results of Hormonal Therapy from Many Achondroplasia Studies in Asia and Europe

Researcher	Tanaka	Hertel	Maccoll	Kertevska	Harada
Year	1998	2005	2016	2016	2017
Country	Japan	Europe	Italy	Macedonia	Japan
Study Design	<i>Clin. Study</i>	<i>RDRS</i>	<i>MA</i>	<i>CS</i>	<i>RCS</i>
Total Patient	42	35	558	1	22
Age (yrs)	3	4	< 8	3	3
Length of Therapy (yrs)	2	5	5	7	10
Length Addition	109 mm	+	+	360 mm	210 mm
Complication	Null	Null	Null	Null	Null

Description:

Clin. Study: Clinical Study, RDRS: Randomized Dose Respon Study, MA; Meta-Analysis, RCS: Retrospective Cohort Study

r-hGH therapy on achondroplasia has raised questions about the safety of the malignancy risk. Growth hormone (GH) has an effector in body tissues, namely insulin growth factor (IGF-1). This compound has strong potency to stimulate cell duplication and prevent cell necrosis. The growth hormone effect goes through the relation of GH and IGF-1 called the GH – IGF axis. This mechanism was proven in a laboratory and tested on animals but not in humans.

r-hGH therapy effect literature that was published is very little. One of these was a cohort

study from Swerdlow, including 24.232 patients with a study time of 17 years. The study did not mention achondroplasia diagnosis but skeletal dysplasia diagnosis in about 358 (1.5%) patients (Swerdlow *et al*, 2015). Swerdlow reports that r-hGH therapy did not affect the malignancy risk and did not cause mortality (Swerdlow *et al*, 2018).

However, Cianfarani reminded us that hormonal therapy on achondroplasia should consider benefits, risks, and costs (Cianfarani, 2019). Comparison of the results of the therapy can be seen in Table 3 below

Table 3. Comparison of the Results of Surgery and Hormonal Therapy On Achondroplasia Patients

Method of Therapy	Patient	Ages	Time of Therapy	Bone Addition	Complication (%)
Surgery	167 children	9 -20 years old	4 years	185 mm	19
Hormone	658 children	3 - 8 years old	5 years	226 mm	0

Literature review showed the characteristics of surgery therapy and hormonal therapy on achondroplasia patients (Table 1 – 3). Both methods can lengthen the bone, but bone lengthening surgery had many complications with high-rate complications. The highly skilled surgeon can't guarantee that there was no complication. Although the surgeons were experienced, paralysis post-surgery could be happening. Without well-prepared surgery and close postoperative monitoring, the surgery will caused disability and even death.

Growth hormone therapy was safe, without complication, and there was no risk for malignancies. Growth hormone (rhGH) met the requirements of achondroplasia drugs. It was in accordance with the modern pharmacotherapy approach. The weakness was that this medicine should be injected into the patient for a long time (Wrobel *et al*, 2021).

CONCLUSION

Based on this scientific evidence from this literature review, it can be concluded that growth hormone therapy is safe and effective in increasing the patient's height. This therapy gives benefit and new hope for achondroplasia patients. This study limitation was the literature data search engine only from google scholar and PubMed. Another limitation is the hormonal therapy literature for achondroplasia patient-reported various dose, frequency, and length of therapy. In addition, most of the research subjects at risk of

malignancy on hormone therapy were not achondroplasia patients.

SUGGESTION

It is still needed to further study about dose, administration frequencies, and length of the hormonal therapy on achondroplasia patients. The study should use a better design like meta-analysis or controlled clinical study. The time of the study should be longer and include children, teenagers, and adults periods.

REFERENCES

Backeljauw P, Cappa M, Kiess W, Law L, Cookson C, *et al*, 2021. Impact of short stature on quality of life: A systematic literature review. In *Growth Hormone and IGF Research*. 57–58 (2021).

Bhusal S, Gautam U, Phuyal R, Choudhary R, Manandhar SR, and Niroula A, 2020. Diagnosis of achondroplasia at birth: A case report. *Journal of the Nepal Medical Association*. 58(222): 119–121. <https://doi.org/10.31729/jnma.4846>

Ceroni JRM, Soarez DCdQ, Testai LdC, Kawahira RCH, Yamamoto GL, Sugayama SMM *et al*, 2018. Natural History of 39 patients with achondroplasia. *Clinics*. 73: e324. <https://doi.org/10.6061/clinics/2018/e324>

Cianfarani S, 2019. Risk of cancer in patients treated with recombinant human growth hormone in childhood. *Annals of Pediatric Endocrinology and Metabolism*. 24(2): 92–

98.
<https://doi.org/10.6065/apem.2019.24.2.92>
- Coi A, Santoro M, Garne E, Pierini A, Addor MC, *et al*, 2019. Epidemiology of achondroplasia: A population-based study in Europe. *American Journal of Medical Genetics, Part A*. 179(9): 1791–1798. <https://doi.org/10.1002/ajmg.a.61289>
- Daugherty A, 2017. Achondroplasia: Etiology, clinical presentation, and management. *Neonatal Network*. 36(6): 337–342. <https://doi.org/10.1891/0730-0832.36.6.337>
- Dossanov B, Trofimchuk V, Lozovoy V, Khmyzov S, Dossanova A, *et al*, 2021. Evaluating the long tubular bone distraction results with an advanced rod monolateral external fixator for achondroplasia. *Scientific Reports*. 11(1): 14727. <https://doi.org/10.1038/s41598-021-94146-z>
- Foreman PK, van Kessel F, van Hoorn R, van den Bosch J, Shediach R, and Landis S, 2020. Birth prevalence of achondroplasia: A systematic literature review and meta-analysis. *American Journal of Medical Genetics, Part A*. 182(10): 2297–2316. <https://doi.org/10.1002/ajmg.a.61787>
- Ginebreda I, Campillo-Recio D, Cárdenas C, Tapiolas J, Rovira P, and Isart A, 2019. Surgical technique and outcomes for bilateral humeral lengthening for achondroplasia: a 26-year experience. *Musculoskeletal Surgery*. 103(3): 257–262. <https://doi.org/10.1007/s12306-018-0583-3>
- Harada D, Namba N, Hanioka Y, Ueyama K, Sakamoto N, *et al*, 2017. Final adult height in long-term growth hormone-treated achondroplasia patients. *European Journal of Pediatrics*. 176(7): 873–879. <https://doi.org/10.1007/s00431-017-2923-y>
- Hertel NT, Eklöf O, Ivarsson S, Aronson S, Westphal O, *et al*, 2005. Growth hormone treatment in 35 prepubertal children with achondroplasia: A five-year dose-response trial. *Acta Paediatrica, International Journal of Paediatrics*. 94(10): 1402–1410. <https://doi.org/10.1080/08035250510039982>
- Hosny GA, 2020. Limb lengthening history, evolution, complications, and current concepts. *Journal of Orthopaedics and Traumatology*. 21(1). <https://doi.org/10.1186/s10195-019-0541-3>
- Ko KR, Shim JS, Chung CH, and Kim JH, 2019. Surgical results of limb lengthening at the femur, tibia, and humerus in patients with achondroplasia. *CIOs Clinics in Orthopedic Surgery*. 11(2): 226–232. <https://doi.org/10.4055/cios.2019.11.2.26>
- Krstevska-Konstantinova M, Stamatova A, and Gucev Z, 2016. Favorable Growth Hormone Treatment Response in a Young Boy with Achondroplasia. *Medical Archives (Sarajevo, Bosnia, and Herzegovina)*. 70(2): 148–150. <https://doi.org/10.5455/medarh.2016.70.148-150>
- Kubota T, Adachi M, Kitaoka T, Hasegawa K, Ohata Y *et al*, 2020. Clinical practice guidelines for achondroplasia. *Clinical Pediatric Endocrinology*. 29(1): 25–42. <https://doi.org/10.1297/cpe.29.25>
- Legeai-Mallet L, and Savarirayan R, 2020. Novel therapeutic approaches for the treatment of achondroplasia. *Bone*. 141(August), 115579. <https://doi.org/10.1016/j.bone.2020.115579>
- Miccoli M, Bertelloni S, and Massart F, 2016. Height Outcome of Recombinant Human Growth Hormone Treatment in Achondroplasia Children: A Meta-Analysis. *Hormone Research in Paediatrics*. 86(1): 27–34. <https://doi.org/10.1159/000446958>
- Ornitz DM, and Legeai-mallet L, 2018. Achondroplasia: Development, Pathogenesis, and Therapy. *Developmental Dynamics*. 246(4): 291–309. <https://doi.org/10.1002/dvdy.24479>
- Paley D, 2021. Extensive Limb Lengthening for Achondroplasia and Hypochondroplasia. *Children*. 8(7): 540. <https://doi.org/10.3390/children8070540>
- Park KW, Garcia RN, Rejuso CA, Choi JW, and Song

- HR, 2015. Limb Lengthening in Patients with Achondroplasia. *Yonsei Medical Journal*. 56(6): 1656. <https://doi.org/10.3349/ymj.2015.56.6.1656>
- Pauli RM, 2019. Achondroplasia: a comprehensive clinical review. *Orphanet Journal of Rare Diseases*. 14(1), 1. <https://doi.org/10.1186/s13023-018-0972-6>
- Pfeiffer KM, Brod M, Smith A, Viuff D, Ota S, and Charlton RW, 2022. Functioning and well-being in older children and adolescents with achondroplasia: A qualitative study. *American Journal of Medical Genetics, Part A*. 188(2): 454–462. <https://doi.org/10.1002/ajmg.a.62534>
- Savarirayan R, Rossiter JP, Hoover-Fong JE, Irving M, Bompadre V, et al, 2018. Best practice guidelines regarding prenatal evaluation and delivery of patients with skeletal dysplasia. *American Journal of Obstetrics and Gynecology*. 219(6): 545–562. <https://doi.org/10.1016/j.ajog.2018.07.017>
- Shabtai L, Jauregui JJ, Herzenberg JE, Gesheff MG, Standard SC, and McClure PK, 2021. Simultaneous bilateral femoral and tibial lengthening in achondroplasia. *Children*. 8(9). <https://doi.org/10.3390/children8090749>
- Supartono B, 2018. Hyaline Cartilage Regeneration on Osteochondral defects by Intraarticular Injection of Human Peripheral Blood CD34+ Cells, Hyaluronic Acid and Growth Factor in a Rat Model. *Biomedical Journal of Scientific & Technical Research*. <https://doi.org/10.26717/bjstr.2018.07.001436>
- Supartono B, Utami AD, and Kusumaningsih P, 2021. Rakitis Nutrisi akibat Diet Vegan pada Ibu Hamil dan Menyusui. *Jurnal Ilmiah Kedokteran Wijaya Kusuma*. 10(2): 194–207. <https://doi.org/10.30742/jikw.v10i2.1435>
- Swerdlow AJ, Cooke R, Albertsson-Wikland K, Borgström B, Butler G, et al, 2015. Description of the SAGhE cohort: A large European study of mortality and cancer incidence risks after childhood treatment with recombinant growth hormone. *Hormone Research in Paediatrics*. 84(3): 172–183. <https://doi.org/10.1159/000435856>
- Swerdlow AJ, Cooke R, Beckers D, and Borgström B, 2018. Cancer risks in patients treated with growth hormone in childhood: the SAGhE European cohort study. *J. Clin Endocrinol Metab*. 102(5): 1661–1672. <https://doi.org/10.1210/jc.2016-2046>.Cancer
- Tanaka H, Kubo T, Yamate T, Ono T, Kanzaki S, and Seino Y, 1998. Effect of growth hormone therapy in children with achondroplasia: growth pattern, hypothalamic-pituitary function, and genotype. *European Journal of Endocrinology*. 138(3): 275–280. <https://doi.org/10.1530/eje.0.1380275>
- Unger S, Bonafé L, and Gouze E, 2017. Current Care and Investigational Therapies in Achondroplasia. *Current Osteoporosis Reports*. 15(2): 53–60. <https://doi.org/10.1007/s11914-017-0347-2>
- Wrobel W, Pach E, and Ben-Skowronek I, 2021. Advantages and Disadvantages of Different Treatment Methods in Achondroplasia: A Review. *International Journal of Molecular Sciences*. 22(11): 5573. <https://doi.org/10.3390/ijms22115573>